

# Heller Myotomy Versus Heller Myotomy With Dor Fundoplication for Achalasia

## A Prospective Randomized Double-Blind Clinical Trial

William O. Richards, MD,\* Alfonso Torquati, MD, MSCI,\* Michael D. Holzman, MD, MPH,\*  
Leena Khaitan, MD, MPH,\* Daniel Byrne, MS,† Rami Lutfi, MD,\* and Kenneth W. Sharp, MD\*

**Objective:** We sought to determine the impact of the addition of Dor fundoplication on the incidence of postoperative gastroesophageal reflux (GER) after Heller myotomy.

**Summary Background Data:** Based only on case series, many surgeons believe that an antireflux procedure should be added to the Heller myotomy. However, no prospective randomized data support this approach.

**Patients and Methods:** In this prospective, randomized, double-blind, institutional review board-approved clinical trial, patients with achalasia were assigned to undergo Heller myotomy or Heller myotomy plus Dor fundoplication. Patients were studied via 24-hour pH study and manometry at 6 months postoperatively. Pathologic GER was defined as distal esophageal time acid exposure time greater than 4.2% per 24-hour period. The outcome variables were analyzed on an intention-to-treat basis.

**Results:** Forty-three patients were enrolled. There were no differences in the baseline characteristics between study groups. Pathologic GER occurred in 10 of 21 patients (47.6%) after Heller and in 2 of 22 patients (9.1%) after Heller plus Dor ( $P = 0.005$ ). Heller plus Dor was associated with a significant reduction in the risk of GER (relative risk 0.11; 95% confidence interval 0.02–0.59;  $P = 0.01$ ). Median distal esophageal acid exposure time was lower in the Heller plus Dor (0.4%; range, 0–16.7) compared with the Heller group (4.9%; range, 0.1–43.6;  $P = 0.001$ ). No significant difference in surgical outcome between the 2 techniques with respect to postoperative lower-esophageal sphincter pressure or postoperative dysphagia score was observed.

**Conclusions:** Heller Myotomy plus Dor Fundoplication was superior to Heller myotomy alone in regard to the incidence of postoperative GER.

(*Ann Surg* 2004;240: 405–415)

From the \*Departments of Surgery and †Medicine and Biostatistics, Vanderbilt University, Medical School, Nashville, Tennessee.

Dr. Khaitan is now a Faculty Member at Emory School of Medicine.

Dr. Torquati was supported by Master of Science in Clinical Investigation, Vanderbilt University.

Reprints: William O. Richards, MD, Department of Surgery, Vanderbilt University Medical Center, D-5219 MCN, Nashville, TN 37232. E-mail: bill.richards@vanderbilt.edu.

Copyright © 2004 by Lippincott Williams & Wilkins

ISSN: 0003-4932/04/24003-0405

DOI: 10.1097/01.sla.0000136940.32255.51

Since the first report of laparoscopic Heller myotomy in 1991 by Shimi et al<sup>1</sup> and thoracoscopic Heller myotomy by Pellegrini et al<sup>2</sup> in 1992, minimally invasive techniques have been increasingly used for the treatment of achalasia. Many surgeons have noticed a distinct change in the referral patterns for treatment of achalasia now that minimally invasive techniques are available. Patti and colleagues<sup>3</sup> in 2002 reported that during the past decade, their center at the University of California, San Francisco, saw a marked increase in the number of patients who were referred for laparoscopic Heller myotomy with a corresponding decrease in use of pneumatic balloon dilation or botulinum toxin injection. Laparoscopic Heller myotomy is the preferred treatment at Vanderbilt, and we have previously reported our results and technique.<sup>4</sup>

A great deal of controversy exists over the appropriate use of antireflux procedures to prevent reflux after myotomy. The arguments for using a partial antireflux procedure with laparoscopic Heller myotomy have been summarized nicely by Peters,<sup>5</sup> and the arguments against the routine use of an antireflux procedure were presented by our group during a Society for Surgery of the Alimentary Tract symposium in 2000.<sup>6</sup>

A recent meta-analysis of laparoscopic Heller myotomy with or without antireflux procedure from 1991 to 2001 was performed by Lyass et al.<sup>7</sup> Pathologic acid exposure was identified by 24-hour pH studies in 7.9% of 489 patients who underwent Heller with partial fundoplication. Forty-seven patients who had previously undergone Heller without antireflux procedure were studied with 24-hour pH monitoring and only 4, or 10%, of the 40 patients had pathologic acid exposure. This meta-analysis concluded “based on the reported data in human subjects that no recommendations could be made regarding the efficacy of partial antireflux procedures in protecting against pathologic gastroesophageal reflux (GER) after esophageal Heller myotomy.” We have completed a study that randomized 43 patients with achalasia to Heller myotomy alone or to Heller myotomy plus Dor fundoplication. The study was designed as a double-blind, parallel-group randomized trial to test the null hypothesis that

the addition of Dor fundoplication will not alter the incidence of pathologic GER in these patients.

## MATERIALS AND METHODS

### Patients

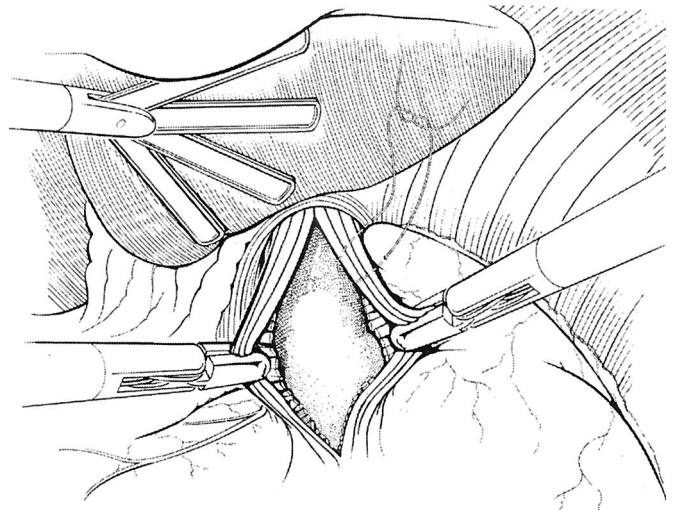
The study, following Institutional Review Board approval, was conducted at Vanderbilt University Medical Center in Nashville, Tennessee. Patients 18 years of age or older who were diagnosed with achalasia were referred from outside facilities and within the institution to the Division of General Surgery. Diagnosis of achalasia was confirmed manometrically by the presence of simultaneous esophageal body contractions and nonrelaxing lower esophageal sphincter (LES). Exclusion criteria included: (1) previous surgical treatment of achalasia; (2) objective evidence of ongoing GER disease; (3) achalasia associated with gastric or esophageal carcinoma; and (4) pregnancy.

### Treatment Allocation

Eligible patients, after giving written informed consent, were assigned to undergo Heller myotomy or Heller myotomy plus Dor fundoplication, based on a randomization schedule generated using a random numbers table. The randomization code was generated using a permuted block size of 4. No other restrictions were used in the randomization procedure. One of the investigators who was not involved in the selection and allocation of patients prepared, coded, and sealed opaque envelopes containing the treatment allocation. After the baseline assessment, the next envelope was handed to the surgeon on the day of surgery to ensure concealment of allocation. All recruited patients and researchers involved in the evaluation of the end points (A.T., L.K., D.B., and R.L.) were blinded to the treatment assigned throughout the whole study period.

### Surgical Technique

Our technique for laparoscopic Heller myotomy has been previously described in detail.<sup>4</sup> Briefly, after the phrenoesophageal ligament is divided, which exposes the anterior gastroesophageal (GE) junction, the myotomy is performed by incising the distal 4 to 6 cm of esophageal musculature. The myotomy is extended 1 to 2 cm onto the gastric cardia using cautery scissors or an ultrasonic scalpel. Intraoperative endoscopy is performed simultaneously with the myotomy to assess the adequacy of the myotomy. For the purposes of our study, in the subjects randomized to fundoplication, an anterior 180° Dor fundoplication was created. The top part of the cardia was sutured to the left crural pillar of the diaphragm and to the left side of the myotomy at the most superior aspect (Fig. 1). Next, the anterior surface of the gastric cardia and fundus were folded upward and toward the patient's right side, placing the anterior gastric wall over the myotomy. Two additional sutures were then placed. The uppermost suture was used to anchor the fundic flap to right side of the

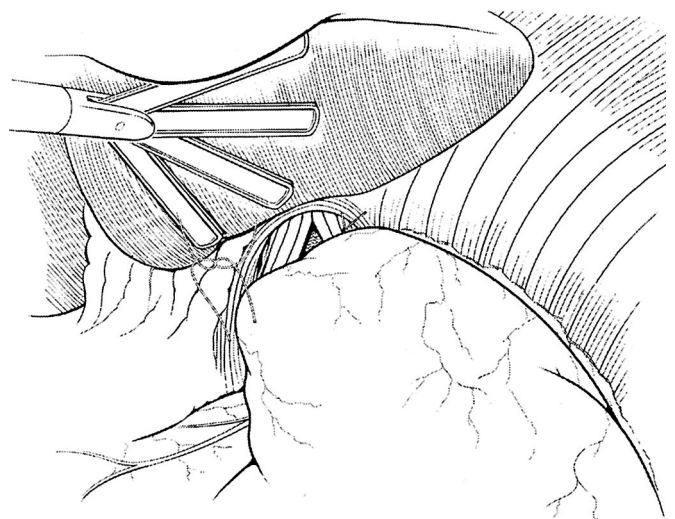


**FIGURE 1.** Edges of esophageal and gastric muscle layers displayed at completion of myotomy. The top part of the cardia is sutured to the left crural pillar of the diaphragm and to the left side of the myotomy at the most superior aspect.

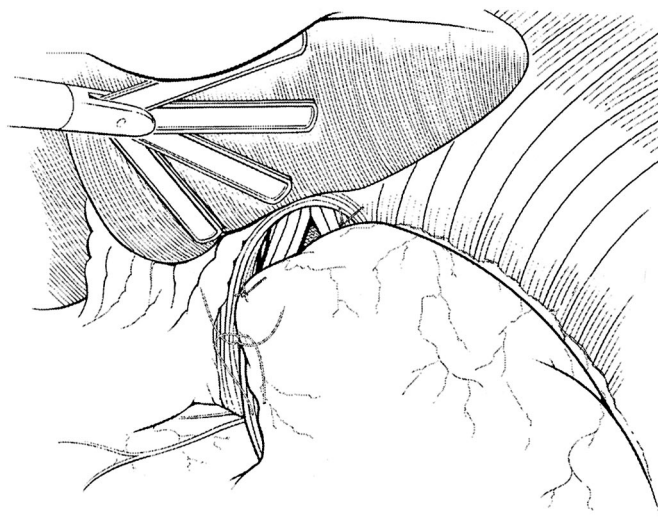
myotomy incorporating the right crural pillar (Fig. 2). With the last suture, the fundus was joined with the inferior aspect of the right side of the myotomy (Fig. 3). Permanent polyester sutures were used (0 Ethibond, Ethicon). All patients were kept in the hospital overnight and selectively underwent a water-soluble contrast swallow (if clinically indicated) on postoperative day 1 before initiation of a liquid diet.

### Follow-up Assessments

Patients were asked to return for a 24-hour pH study and stationary manometry 3-5 months after the surgery as



**FIGURE 2.** Creation of the Dor fundoplication. The uppermost suture is used to anchor the fundic flap to right side of the myotomy incorporating the right crural pillar.



**FIGURE 3.** Completion of the Dor fundoplication. The gastric fundus is joined with the inferior aspect of the right side of the myotomy.

part of the study protocol. An investigator blinded to the randomization evaluated the manometric and 24-hour pH data. Standard esophageal manometry was performed using a 6-channel probe (Sandhill Scientific, Highlands Ranch, CO) with a pull-through technique. The LES pressure was defined as the difference between the end expiratory gastric baseline pressure and the middle end expiratory pressure just distal to the respiratory inversion point.

Immediately after esophageal manometry, patients underwent 24-hour pH monitoring study using a 2-channel pH probe (Sandhill Scientific). The distal pH sensor was placed 5 cm above the upper border of the manometrically determined LES. The probe was attached to a portable monitor that recorded intraesophageal pH data for 24 hours. The recorder allowed patients to note their symptoms, time at which meals were consumed, and body position, by depressing the appropriate event button. Patients were tested while off all antisecretory or promotility medications and instructed to avoid all foods that could falsely alter the esophageal pH. Data analysis was performed using a Sandhill Scientific software, which reported percentage of time the pH was  $<4$  in the supine and upright position, as well as the Johnson-DeMeester score, which is calculated from the following 6 parameters to include the total percentage of time the pH was  $<4$ ; the percentage of time the pH was  $<4$  while upright; the percentage of time the pH was  $<4$  while supine; the number of episodes the pH was  $<4$ ; the number of episodes the pH was  $<4$  for  $\geq 5$  minutes; and the duration of the longest episode where the pH was  $<4$ .

Before the manometry, each patient completed a questionnaire related to the severity and frequency of dysphagia

symptoms after the surgery. The dysphagia score was calculated by combining the frequency of dysphagia (0 = never, 1 =  $<1$  day/wk, 2 = 1 day/wk, 3 = 2–3 days/wk, 4 = 4–6 days/wk, 5 = daily) with the severity (0 = none, 1 = very mild, 2 = mild, 3 = moderate, 4 = moderately severe, 5 = severe).

### Outcome Measures

The primary outcome measure was incidence of pathologic GER in the Heller and Heller plus Dor groups. The presence of pathologic GER was established when the total time with pH  $<4$  was more than 4.2% per 24-hour period. Secondary end points measured included: total percentage of time the pH was  $<4$  per 24-hour period, dysphagia score, and postoperative LES pressure.

### Statistical Analysis

The number of patients included in the study was based on the sample size estimation<sup>8</sup> for our primary end point: incidence of pathologic GER in the 2 groups. We estimated that 20 patients would be required in each group for the study to have a power of 80% to detect a difference of 35% in the incidence of pathologic GER between the Heller and Heller plus Dor groups with a 2-sided  $\alpha$  value of 0.05. We allowed for the possibility of incomplete pH studies and included a total of 43 patients in this study.

The data are presented as median (25th, 75th percentiles, and range) for continuous variables, and as counts or proportions (%) for categorical variables. Differences between groups were compared with the use of a 2-sided type I error Student *t* test or the Mann–Whitney *U* test for continuous variables. Two-sided  $\chi^2$  test or Fisher exact test (whenever an expected cell value was  $<5$ ) was used for categorical variables. Logistic regression was used to determine the relative risk of postoperative pathologic GER according to the surgical procedure. The SPSS statistical software program (version 11.0, SPSS, Chicago, IL) was used for all analyses. The outcome variables were analyzed on an intention-to-treat basis. All reported *P* values are 2-sided. No interim analyses were conducted during the course of this study.

## RESULTS

### Patient Populations

From December 2000 to October 2003, 43 patients underwent randomization: 21 underwent Heller myotomy alone and 22 underwent Heller plus Dor fundoplication. The baseline characteristics were similar in the 2 groups (Table 1). The median age was 50 years in both groups. The gender distribution of patients was similar in the 2 groups. There was no significant difference in the preoperative median dysphagia score and LES pressure in the 2 groups. In 8 patients, preoperative LES pressure was not determined because the

manometry catheter could not be passed beyond the tight LES (4 in the Heller group, 4 in the Heller plus Dor group).

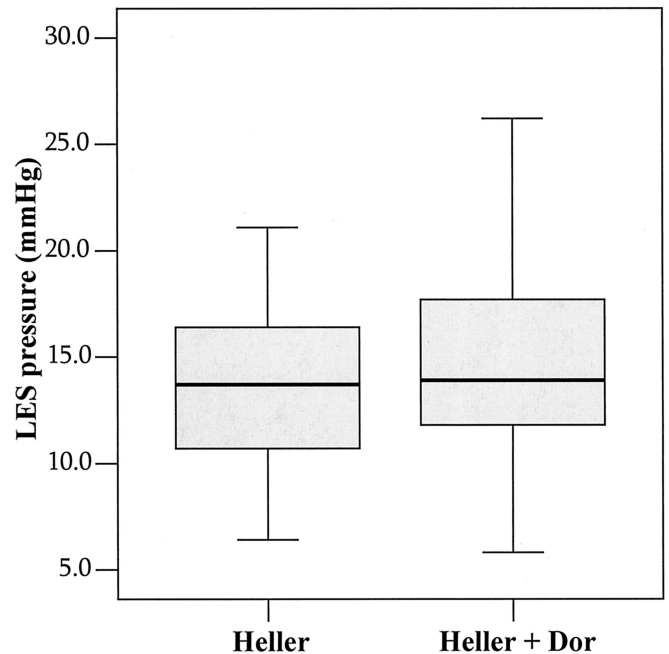
**Operative Data and Perioperative Follow-up**

All patients underwent the procedure that was allocated them by the randomization table. All surgeries were completed with laparoscopic technique. The median operating room time was 85 minutes (range, 54–180) in the Heller group and 125 minutes (range, 83–415) in the Heller plus Dor group ( $P = 0.003$ ). The median hospital stay was 1 day (range, 1–2 days) in both groups. No postoperative complications or perioperative deaths occurred. No patient had a perforation revealed on the postoperative contrast swallow when performed. One patient randomized to Heller plus Dor, 18 months after the procedure, underwent redo Heller myotomy for recurrent dysphagia secondary to incomplete myotomy. The first myotomy left the LES length unchanged and slightly decreased the LES pressure from 20 mm Hg to 17.4 mm Hg.

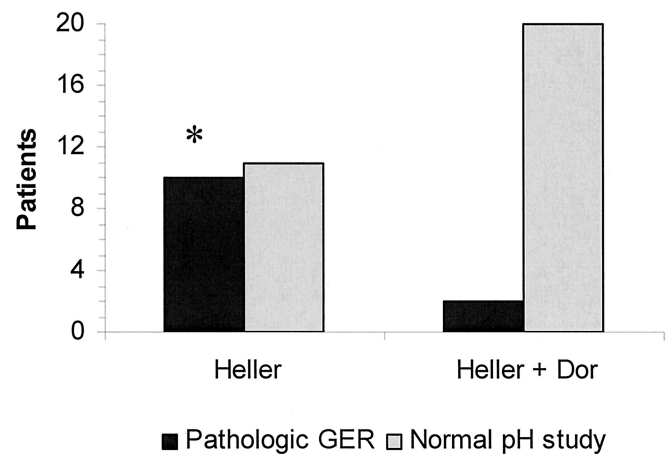
**Objective Response to Treatment**

Esophageal pH study and manometry was performed at a median of 6 months (range, 3–8) after surgery. As shown in Figure 4, median LES pressure was similar: 13.7 mm Hg (range, 6.4–25.9) in the Heller group and 13.9 mm Hg (range, 5.8–26.8) in the Heller plus Dor group. The median length of the LES pressure zone was 3.5 cm (range, 2–6) in the Heller group and 3.5 cm (range, 3.2–5.5) in the Heller plus Dor group ( $P = 0.58$ ).

Postoperative 24-hour pH data were available for 39 patients (18 patients in the Heller group and 21 in the Heller plus Dor group). One patient pulled out the pH probe after 2 hours of recording, and the remainder of patients were not willing to undergo 24-hour pH study. There were no systematic clinical differences between those who underwent 24-hour pH study and those who did not. As shown in Figure 5, the incidence of pathologic GER was 47.6% (10 of 21 patients) in the Heller group and 9.1% (2 of 22 patients) in the



**FIGURE 4.** Postoperative LES pressure in the 2 groups. Data are shown as median (horizontal line), interquartile range (box), and 5th to 95th percentile (vertical line). In both groups, the pressure dropped significantly from preoperative values.



**FIGURE 5.** Incidence of pathologic GER in the 2 groups using the intention to treat analysis. \* $P = 0.005$  versus Heller plus Dor.

**TABLE 1.** Base-line Characteristics of the 2 Groups of Patients

Characteristics	Heller (n = 21)	Heller + Dor (n = 22)	P Value
Age at enrollment (years) (mean and range)	50 (24–76)	50 (22–73)	0.57
Female, no. (%)	10 (47.6)	12 (54.5)	0.65
Preoperative LES pressure (mm Hg) (mean and range)	35 (14–120)	33 (20–120)	0.76
Preoperative Dysphagia Score (mean and range)	9 (5–10)	8 (5–10)	0.91

Heller plus Dor group using an intention-to-treat analysis ( $P = 0.005$ ). According to the principle of intention to treat, patients without 24-hour pH data were classified as not having pathologic GER. As shown in Figure 6, patients in the Heller group showed significantly higher median acid exposure (4.9%; range, 0.1–43.6) to the distal esophagus than the Heller plus Dor group (0.4%; range, 0–16.7;  $P = 0.001$ ).

Figure 7 shows the distribution of DeMeester scores in the 2 groups. The median score was higher in the Heller group (31.5; range, 3–270) than in the Heller plus Dor group (6.5; range, 5–125;  $P = 0.01$ ). Table 2 includes other 24-hour pH study parameters. The Heller group was characterized by significantly prolonged esophageal acid exposure while supine and by a higher number of GER episodes than the Heller-Dor group. Overall, the Heller plus Dor procedure was associated with a significant reduction in the risk of pathologic GER (relative risk 0.11; 95% confidence interval 0.02–0.59;  $P = 0.01$ ).

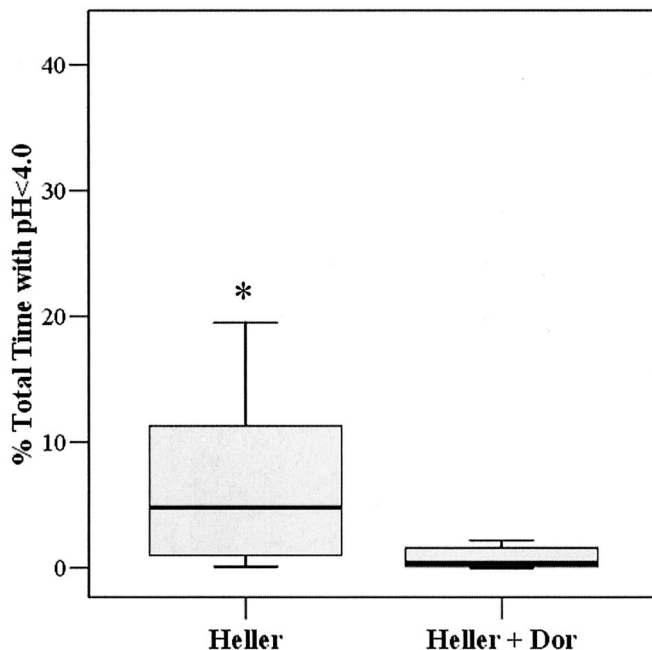
### Subjective Response to Treatment

As shown in Figure 8, patients undergoing Heller myotomy had a median decrease in dysphagia score of 9 points whereas patients after Heller plus Dor decreased their dysphagia score by a median of 8 points ( $P = 0.79$ ).

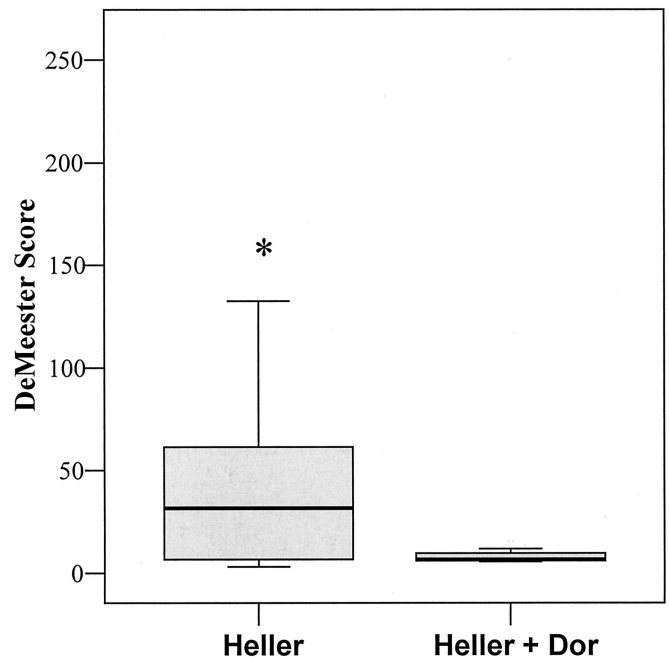
## DISCUSSION

### History

Arguments for and against addition of a fundoplication after Heller myotomy have been going on for many years.<sup>5,6</sup> Most surgeons who have written on this subject in the last decade would argue for a partial wrap to prevent reflux after myotomy. Large series from across the globe have shown excellent results with this approach. Bonavina et al<sup>9</sup> reported



**FIGURE 6.** Distal esophageal acid exposure in the 2 groups. Data are shown as median (horizontal line), interquartile range (box), and 5th to 95th percentile (vertical line). \* $P = 0.001$  versus Heller plus Dor.



**FIGURE 7.** DeMeester scores in the 2 groups. Data are shown as median (horizontal line), interquartile range (box), and 5th to 95th percentile (vertical line). \* $P = 0.01$  versus Heller plus Dor.

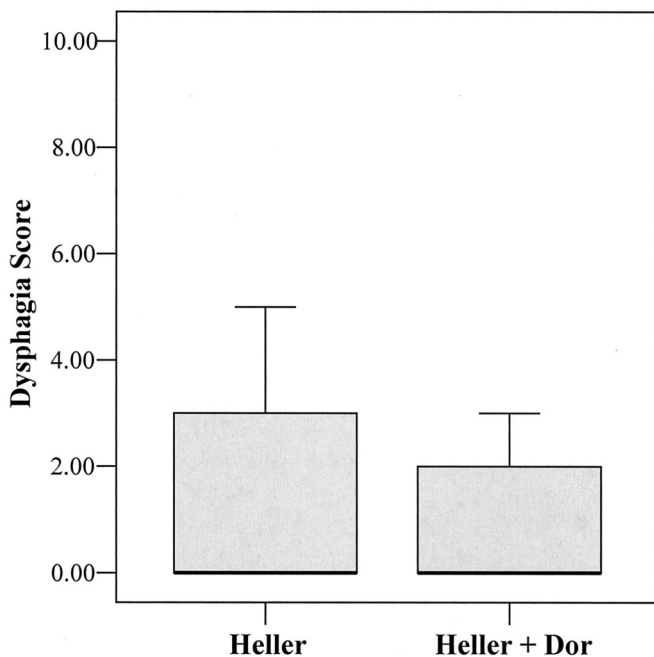
**TABLE 2.** Detailed 24-Hour pH Data Analysis of the 2 Groups of Patients

Characteristics	Heller (n = 18)	Heller + Dor (n = 21)	P Value
Time (%) pH <4 while upright	8.1 ± 10.4	0.8 ± 1.1	0.015
Time (%) pH <4 while supine	9.1 ± 18.3	2.0 ± 6.9	0.002
No. episodes with pH <4	113 ± 128	25 ± 42	0.001
No. episodes with pH <4 for ≥5 min	3.4 ± 4.7	0.5 ± 1.6	0.001

Data expressed as mean ± standard deviation.

on 206 patients with achalasia who underwent open myotomy and anterior Dor fundoplication. Pathologic acid exposure was found in 7/81 (8.6%) patients who underwent testing and 93.8% of patients had good to excellent results. Laparoscopic myotomy with Dor fundoplication has been studied by several authors and found to be associated with a low rate of GER (5.7–10%) by 24 hour pH studies.<sup>9–12</sup>

Many surgeons have been reluctant to use what they consider to be an inadequate antireflux procedure such as the Dor and have dissected the entire esophageal hiatus and performed a 270-degree Toupet fundoplication. They also



**FIGURE 8.** Postoperative dysphagia scores in the 2 groups. Data are shown as median (horizontal line), interquartile range (box), and 5th to 95th percentile (vertical line).

have reported excellent results with this approach, both with relief of dysphagia and low rates of postoperative reflux. Early reports from Swanstrom report no pathologic reflux in 9 patients studied out of a cohort of 12.<sup>13</sup> A later study from Pellegrini and Pennings reported no significant differences between esophageal acid exposure times between Heller plus Dor (5.9%) and Heller with Toupet fundoplication (6.0%), although 54% of the patients undergoing Heller plus Toupet had abnormal DeMeester scores ( $>14.7$ ).<sup>13</sup> Hunter reported excellent results with the Heller plus Toupet fundoplication and would preferentially perform this operation except in patients with megaesophagus in which case posterior fundoplication angulates the distal esophagus which impairs esophageal clearance.<sup>14</sup>

Before the advent of laparoscopic Heller myotomy, Ellis was the most vocal proponent for esophagomyotomy limited to the distal esophagus that left a small sub hiatal portion of the lower esophageal sphincter intact.<sup>15,16</sup> This thoracic approach, in Dr Ellis's hands, gave excellent results with a low incidence of postoperative GER. He postulated that the remnant of LES left in place protected against reflux. He reported LES pressure after limited Heller myotomy of  $14.5 \pm 1.4$  mm Hg almost identical to the LES pressure found in this study after either operation. We have been a vocal proponent of laparoscopic Heller myotomy without antireflux procedure during the last decade.<sup>6,17</sup> We believe that avoiding dissection of the lateral and posterior attachments to the GE

junction minimizes disruption to the angle of His and thus reduces postoperative GER. Our previous retrospective analysis of 24-hour pH studies after Heller myotomy alone indicated that only 4 of 31 (12.9%) patients studied had pathologic esophageal acid exposure.<sup>6,17</sup> The extent of myotomy was determined using simultaneous intraoperative endoscopy. This may have limited the extent of myotomy compared with other surgical studies but we feel that it is the best technique to assess adequacy of the myotomy.

### Primary End Point

Prior to this study there was no level 1 data to support the use of a partial fundoplication with Heller myotomy. We designed a randomized clinical trial to answer the question regarding the efficacy of a partial 180 degree anterior fundoplication or Dor fundoplication added to the esophageal myotomy for prevention of pathologic GER in patients with achalasia. The primary end point was the percent of patients who developed pathologic acid exposure. Secondary end-points of this study were distal esophageal acid exposure, DeMeester score, dysphagia score, and postoperative LES pressure.

This randomized double blinded clinical trial absolutely demonstrates that Heller myotomy plus Dor fundoplication prevents pathologic acid exposure after Heller myotomy for achalasia. The differences in incidence of pathologic GER between the 2 groups are quite remarkable. Not only did 47.6% of the patients undergoing Heller myotomy alone have pathologic GER, as ascertained by a percent total time of acid exposure greater than 4.2% in a 24-hour period, but also the median distal esophageal acid exposure time was remarkably higher (4.9%) compared with the Heller with Dor fundoplication group (0.4%). In many of the Heller alone patients, we saw sustained acid exposure times in the distal esophagus that could lead to severe acid erosion of the esophagus. The 2 patients in the Heller plus Dor fundoplication group who had pathologic acid exposure had only slightly greater than 4.2% acid exposure whereas those with Heller alone had greater acid exposure time. It is surprising how effective the Dor was in preventing pathologic GER after Heller myotomy in this study. We were able to achieve a very high rate of follow-up, which gives us absolute data to base the conclusions of the study. Furthermore, results were analyzed on an intention-to-treat basis and the majority of patients who did not undergo pH testing were in the Heller alone group thus skewing the results favoring Heller alone.

### Secondary End Points

In this study there was no drawback to the performance of a Dor fundoplication. The addition of the Dor added little time to the operative procedure. Postoperative LES pressures were no different between the 2 groups. Moreover resolution of dysphagia symptoms was equal in both groups. Although

some authors<sup>13,14</sup> argue that the Toupet partial fundoplication is more effective for prevention of reflux, there are many advocates for the Dor fundoplication after Heller myotomy. Some authors even go so far as to say the Dor fundoplication is a technically more difficult operative procedure. The 3 surgeons (W.O.R., K.W.S., M.D.H.) who performed the procedures all found the Dor fundoplication easy to add to the myotomy, and in no case did addition of the Dor fundoplication add to or cause postoperative dysphagia or necessity for revision. Thus, we, like many others, believe the Dor fundoplication is an appropriate partial fundoplication after esophagocardiomyotomy for treatment of achalasia.<sup>3,12,18,19</sup>

### Heller Plus Nissen Fundoplication

A recent study randomized patients with achalasia between Heller esophagomyotomy and Heller plus floppy Nissen fundoplication. Falkenbach and colleagues, between 1984 and 1995, randomized a total of 20 patients between the 2 groups.<sup>20</sup> Postoperative pathologic GER developed in 13% of patients undergoing Heller alone and in only 0.15% of the patients in the Heller plus Nissen fundoplication group. In addition, they found 6 out of 9 patients, after Heller myotomy alone, developed erosive esophagitis, including 2 of 9 that developed Barrett's esophagus. No patients in the Heller plus Nissen fundoplication required postoperative continuous acid-reducing drugs, nor did any of these patients develop severe esophagitis or Barrett's esophagus. The authors stated unequivocally that the addition of a 360-degree fundoplication prevented GER after Heller myotomy and did not add dysphagia in the majority of patients undergoing this combined procedure. However, the authors also report a difference between lower esophageal sphincter pressure between the Heller, and Heller plus Nissen group (1.7 mm Hg versus 7.5 mm Hg, respectively). In addition, 3 years after surgery, one of the patients undergoing Heller plus Nissen fundoplication was regarded as a total treatment failure and underwent esophagectomy for treatment. This raises concerns that addition of a Nissen wrap after Heller myotomy may retard esophageal clearance and result in progressive dilation of the aperistaltic esophagus and recurrent dysphagia. The difference in LES pressure in the 2 groups also raises red flags that a 360-degree wrap may impair esophageal emptying and negate the original intent of the procedure, ie, resolution of dysphagia.

Other investigators have come to the same conclusion regarding Nissen after Heller. Topart studied patients who underwent Heller myotomy plus Nissen fundoplication.<sup>21</sup> In his study, he identified progressive esophageal dilation that resulted in an extremely high reoperation rate to either take down the Nissen fundoplications or perform esophagectomy. Twenty-nine percent of the patients undergoing Heller myotomy plus Nissen fundoplication needed another operation to address progressive esophageal dilation and recurrent dys-

phagia. Most authors on the subject would agree that Nissen after Heller myotomy will cause progressive esophageal failure and is not recommended.<sup>3,22</sup>

Partial fundoplication does not obstruct the esophagus to the same degree that a total 360-degree fundoplication does. Thus the very reason for operating on these patients to alleviate their dysphagia symptoms seems to be abrogated by the performance of a 360-degree fundoplication to prevent reflux. A slightly higher reflux rate seems to be a low price to pay for long-term alleviation of dysphagia. This randomized, controlled clinical trial suggests very strongly that excellent results can be obtained with the approach taken, ie, Heller plus Dor fundoplication, and reduce the number of patients with pathologic acid exposure to a medically manageable level.

### Extended Myotomy

Others have suggested extension of the myotomy onto the gastric wall is extremely important to the outcome. Oelschlager and colleagues have written about their experience at the University of Washington with an extended Heller myotomy.<sup>23</sup> In this treatment, they extend the Heller myotomy down 3 cm from the external GE junction and performed a Toupet posterior 270-degree fundoplication to prevent GER postoperatively. These authors compared this treatment of extended gastric myotomy to standard myotomy 1.5 cm below the external GE junction with addition of a Dor fundoplication. They found a significant difference in LES pressures with the extended myotomy group having a much lower pressure (9.5 mm Hg versus 15.8 mm Hg). They noted 9 of 52 (17%) patients undergoing the shorter esophagogastric myotomy and Dor fundoplication had recurrent dysphagia whereas only 2 patients (3%) developed recurrent dysphagia after extended gastric myotomy and Toupet fundoplication. Pathologic reflux occurred in both groups, but there was no difference in the number of pathologic DeMeester scores (32% in the standard myotomy plus Dor fundoplication versus 54% in the extended myotomy and Toupet fundoplication). Nevertheless, these investigators pointed out patients after either of these 2 partial fundoplications can have pathologic acid exposure. Randomizing patients into length of myotomy and type of partial fundoplication to obtain level 1 data will be the best way to solve the problem of optimal surgical technique. Our randomized controlled trial gives very strong support for a laparoscopic approach, with endoscopic guidance to ascertain the length of myotomy and addition of a Dor partial fundoplication to reduce postoperative GERD.

The anatomy of the muscle fibers around the GE junction may play an important role in the results after Heller myotomy. Korn and colleagues<sup>24</sup> removed the entire esophagus from a patient with end stage achalasia and examined the location of the stenotic area and the relative contribution

of the 2 muscle fibers to the high pressure non relaxing zone. They found that both the semicircular (clasp) fibers and the oblique (sling) fibers were involved in the pathology of achalasia. Simulations of myotomies at different areas of the GE junction illustrated that a myotomy closer to the lesser curve would section only the clasp fibers while a myotomy on the greater curve side would section only the sling fibers. Myotomy anteriorly would cut both muscles thus making it likely those even small differences in technique may lead to significant differences in postoperative outcome. In this study, the surgical technique was standardized as much as possible to reduce variances in postoperative outcome based on differences in technique. Our technique dictated myotomy anteriorly and to the left of the anterior vagus. This resulted in sectioning both muscle groups when brought down far enough from the GE junction. Relief of dysphagia was excellent in both groups. Thus we feel anterior myotomy 1–2 cm onto the stomach with endoscopic visualization of the adequacy of myotomy has created excellent results in this experience.

### CONCLUSIONS

To our knowledge, this is the first reported randomized trial comparing laparoscopic Heller myotomy alone to Heller plus partial Dor fundoplication for treatment of achalasia. The aim of the study was to ascertain if addition of a Dor fundoplication would change pathologic acid exposure after myotomy of the LES. Secondary endpoints, used to evaluate the effectiveness of the procedure, such as dysphagia and postoperative LES pressure were no different in the 2 groups. Results of this study indicate that addition of a Dor antireflux procedure reduces the risk of pathologic GER by 9-fold after laparoscopic Heller myotomy.

### ACKNOWLEDGMENTS

The authors like to thank Joan Kaiser, RN, MA, for her help in the follow-up of these patients.

### REFERENCES

- Shimi S, Nathanson LK, Cuschieri A. Laparoscopic cardiomyotomy for achalasia. *J R Coll Surg Edinb*. 1991;36:152–154.
- Pellegrini C, Wetter LA, Patti M, et al. Thoracoscopic esophagomyotomy. Initial experience with a new approach for the treatment of achalasia. *Ann Surg*. 1992;216:291–296; discussion 296–299.
- Patti MG, Fisichella PM, Perretta S, et al. Impact of minimally invasive surgery on the treatment of esophageal achalasia: a decade of change. *J Am Coll Surg*. 2003;196:698–703; discussion 703–705.
- Sharp KW, Khaitan L, Scholz S, et al. 100 consecutive minimally invasive Heller myotomies: lessons learned. *Ann Surg*. 2002;235:631–638; discussion 638–639.
- Peters JH. An antireflux procedure is critical to the long-term outcome of esophageal myotomy for achalasia. *J Gastrointest Surg*. 2001;5:17–20.
- Richards WO, Sharp KW, Holzman MD. An antireflux procedure should not routinely be added to a Heller myotomy. *J Gastrointest Surg*. 2001;5:13–16.
- Lyass S, Thoman D, Steiner JP, et al. Current status of an antireflux procedure in laparoscopic Heller myotomy. *Surg Endosc*. 2003;17:554–558.
- Dupont WD, Plumer WD. PS power and sample size program available for free on the Internet. *Controlled Clin Trials*. 1997;18:274.
- Bonavina L, Nosadini A, Bardini R, et al. Primary treatment of esophageal achalasia. Long-term results of myotomy and Dor fundoplication. *Arch Surg*. 1992;127(2):222–226; discussion 227.
- Anselmino M, Zaninotto G, Costantini M, et al. One-year follow-up after laparoscopic Heller-Dor operation for esophageal achalasia. *Surg Endosc*. 1997;11:3–7.
- Patti MG, Molena D, Fisichella PM, et al. Laparoscopic Heller myotomy and Dor fundoplication for achalasia: analysis of successes and failures. *Arch Surg*. 2001;136:870–877.
- Ancona E, Peracchia A, Zaninotto G, et al. Heller laparoscopic cardiomyotomy with antireflux anterior fundoplication (Dor) in the treatment of esophageal achalasia. *Surg Endosc*. 1993;7:459–461.
- Swanstrom LL, Pennings J. Laparoscopic esophagomyotomy for achalasia. *Surg Endosc*. 1995;9:286–290; discussion 290–292.
- Hunter JG, Trus TL, Branum GD, et al. Laparoscopic Heller myotomy and fundoplication for achalasia. *Ann Surg*. 1997;225:655–664; discussion 664–665.
- Ellis FH Jr, Watkins EJ, Gibb SP, et al. Ten to 20-year clinical results after short esophagomyotomy without an antireflux procedure (modified Heller operation) for esophageal achalasia. *Eur J Cardiothorac Surg*. 1992;6:86–89; discussion 90.
- Ellis FH Jr. Oesophagomyotomy for achalasia: a 22-year experience. *Br J Surg*. 1993;80:882–885.
- Richards WO, Clements RH, Wang PC, et al. Prevalence of gastroesophageal reflux after laparoscopic Heller myotomy. *Surg Endosc*. 1999;13:1010–1014.
- Donahue PE, Horgan S, Liu KJ, et al. Floppy Dor fundoplication after esophagocardiomyotomy for achalasia. *Surgery*. 2002;132:716–722; discussion 722–723.
- Mattioli G, Esposito C, Prato AP, et al. Results of the laparoscopic Heller-Dor procedure for pediatric esophageal achalasia. *Surg Endosc*. 2003;17:1650–1652.
- Falkenback D, Johansson J, Oberg S, et al. Heller's esophagomyotomy with or without a 360 degrees floppy Nissen fundoplication for achalasia. Long-term results from a prospective randomized study. *Dis Esophagus*. 2003;16:284–290.
- Topart P, Deschamps C, Taillefer R, et al. Long-term effect of total fundoplication on the myotomized esophagus. *Ann Thorac Surg*. 1992;54:1046–1051; discussion 1051–1052.
- Wills VL, Hunt DR. Functional outcome after Heller myotomy and fundoplication for achalasia. *J Gastrointest Surg*. 2001;5:408–413.
- Oeschlager BK, Chang L, Pellegrini CA. Improved outcome after extended gastric myotomy for achalasia. *Arch Surg*. 2003;138:490–495; discussion 495–497.
- Korn O, Braghetto I, Burdiles P, et al. Cardiomyotomy in achalasia: which fibers do we cut? *Dis Esophagus*. 2000;13:104–107; discussion 108–109.

## Discussions

DR. CARLOS A. PELLEGRINI (SEATTLE, WASHINGTON): The authors should be congratulated for designing a simple, randomized, double-blind study to answer a very specific question. The study was conducted in a single institution, over a short period of time, appropriately powered, using the same surgical technique in all patients, and all patients underwent the appropriate postoperative studies. It is hard to ask for a better study.

The authors have shown that an antireflux procedure added to a Heller myotomy decreases the incidence of ab-



normal reflux without increasing the rate of dysphasia. Indeed, as you saw, abnormal reflux was present in 40% of patients who had the Heller alone and in only 9% of patients who had the Heller and the antireflux procedure.

As you recall, some 12 years ago we reported to this Association a series of patients who had a myotomy without an antireflux procedure. We then found that these patients had the 50% incidence of reflux as reported in the control group today, and decided that we would use an antireflux procedure routinely. On the other hand, in several previous presentations the authors have shown that a Heller myotomy alone yielded only a 12 to 14% incidence of abnormal reflux. So my first question is a bit of an intellectual curiosity, but what led you to design this study, since your group had such a low incidence of reflux? Furthermore, why do you think you have observed now a 48% incidence of abnormal reflux in the control group if you are doing the same operation you did before?

My second question has to do with the length of the myotomy. As you know, we have recommended approximately 3 centimeters below the GE junction, and we have noticed that the incidence of reflux is greater the greater the length of the myotomy. In your paper, you describe using endoscopy to determine the length of the myotomy and you tell us that when you measure it, it is about 1 to 2 centimeters below the GE junction only. Could you elaborate for us what is the endoscopic finding that determines the completeness of the myotomy? In other words, how far do you go and when do you stop and why?

My third question has to do with this 1 to 2 centimeter issue. I notice that the average LES pressure that you showed was about 13 to 14 millimeters of mercury and you have already had one patient that you describe in your manuscript that required re-myotomy for the short myotomy. I predict that over time, since this study is just a short follow-up right now, you are going to see a much higher incidence of recurrence rate of dysphagia if the pressure remains above 10. One of the benefits of doing the longer myotomy that we propose is that the pressure is lower than 10 millimeters of mercury.

I believe this is an excellent study and a very well written paper and I recommend it to the membership. I congratulate you on carrying out the study and giving us a definitive answer for the operation for achalasia.

DR. WILLIAM O. RICHARDS (NASHVILLE, TENNESSEE): Thank you, Dr. Pellegrini, for your very kind comments.

Your first question was, what led to the study? Well, it was really quite honestly the drubbing that I encountered during a SSAT symposium. Some of my colleagues told me that I was roundly beaten in a debate forum with Jeff Peters, and we set out to test the hypothesis that Heller was equal to Heller-Dor.

Your second question was, why now do we describe 48% of our patients with pathologic reflux where previously we only showed 12 to 14%? I think that is best answered by a study that is going to be presented at the SSAT in May by my colleague, Dr. Torquati. He did a multivariate analysis looking at the risk factors for developing gastroesophageal reflux after Heller myotomy. He found out that age less than 35 and preoperative LES pressure less than 25, were many times more likely to be associated with postoperative gastroesophageal reflux. Therefore, I suspect that the 24 patients that we studied out of the 110 patients that we had done at that time with Heller myotomy were perhaps older patients with higher LES pressures and therefore had a lower incidence of gastroesophageal reflux.

Your third question was, what was the endoscopic evaluation? How do we identify the adequacy of the myotomy? What endoscopic signs are there? I guess it is a little bit like pornography, or at least the Supreme Court ruling, you know it when you see it, and this requires experience doing it. As we have gained experience, we have gotten a better Heller myotomy. But basically I think that endoscopic evaluation is fairly good. I think to improve it, we might think about doing intraoperative manometry. But we have not done that yet.

The fourth question was about our LES pressures. And indeed we have shown in this paper that our mean LES pressures postoperatively in both groups are somewhere between 13 and 15. The question is, shouldn't a longer myotomy, as you have recently published, reduce those pressures and lead to better long-term results? I don't know the answer to that. It is certainly something that we did not look at. It is hard to argue with the dysphagia score, because our median dysphagia score postoperatively was zero. But there were 2 patients, one in each group, that clearly had an inadequate myotomy.

The USC group, Tom DeMeester and Jeff Peters, have recently published a paper that describes the multivariate analysis of patients undergoing Heller myotomy plus partial fundoplication and which patients get the best results in terms of relief of dysphagia. What they identified was that the most significant preoperative factor that predicts relief of dysphagia is preoperative LES pressure. For example, when they have a pre-op LES pressure of greater than 46 mmHg, they virtually have no postoperative dysphagia. If they had a preoperative LES pressure of less than 26, 60% of their patients had inadequate relief with the Heller myotomy. So I think that there are a lot of things that play into relief of dysphagia and long-term results. Certainly, I hope to be back at this Association in 5 to 10 years to report the long-term follow-up of these patients after Heller myotomy.

DR. PHILIP E. DONAHUE (CHICAGO, ILLINOIS): Dr. Richards, you have given us Type 1 evidence about the incidence of reflux. The question is, how symptomatic were these

patients? When we first proposed ECM (esophageal cardiomyotomy) for achalasia, we didn't have PPIs or H<sub>2</sub> receptor blockers, and postoperative reflux was sometimes disabling and a very, very challenging problem.

Your patients with the long myotomy without fundoplication have been converted into what many gastroenterologists treat on an ongoing basis, patients with a very low LES who usually respond pretty well to antisecretory medications. My question for you then is, how symptomatic were the patients? Have you had to offer them additional surgical treatment or endoscopic alternatives to bolster some of the antireflux mechanisms at the cardia?

It is an outstanding study that you presented, and my compliments to you and your team.

DR. WILLIAM O. RICHARDS (NASHVILLE, TENNESSEE): Thank you, Dr. Donahue. The question is, how symptomatic are these patients? I think the problem with achalasia is that many of the symptoms of GERD that are routinely identified by quality-of-life questionnaires are the same symptoms that they have of regurgitation.

So it is very, very common to see high GERD scores on these quality-of-life instruments preoperatively in patients with achalasia. That is why up to 50% of the patients are actually put on PPIs by the primary care physicians thinking that they have primary GERD and they don't.

Postoperatively, these GERD symptoms are dramatically reduced because the regurgitation is improved. So I think that we have found that there is very poor correlation between symptoms and actual pathologic reflux.

So we believe that every patient undergoing laparoscopic or open Heller myotomy should have a pH study and endoscopic surveillance at some point in time. We have not offered additional surgical procedures to any of our patients undergoing Heller myotomy. But when we have determined that they do have pathologic reflux, we do place them on PPI medication.

DR. JOHN G. HUNTER (PORTLAND, OREGON): Dr. Richards, congratulations on a much needed RCT and welcome to The American Surgical. I think Dr. Pellegrini and Dr. Donahue have asked most of my questions, so I will only ask one. Why did you choose the Dor-Fundoplication anteriorly as opposed to the posterior partial fundoplication, generally called the Toupet, which Dr. Pellegrini, myself and many others prefer?

DR. WILLIAM O. RICHARDS (NASHVILLE, TENNESSEE): We chose the Dor-Fundoplication primarily because it is a much simpler operation. I think the other important reason for us is that fairly routinely if we did have intraoperative perforations of the mucosa in our previous practice we would often do a

Dor-Fundoplication to bolster the mucosal repair and thus sleep much better at night.

DR. ALEX G. LITTLE (DAYTON, OHIO): Dr. Hunter just asked my question, so a quick comment that you might react to. I prefer the Dor to the Toupet because you leave so much of the normal hiatus, presumably normal hiatus, undisturbed. And I think that with minimal anterior dissection you get to the esophagus and leave maybe 60% of the normal attachments in place, which presumably is helpful in protecting and preserving the antireflux mechanism in the future. I would appreciate your thoughts about that.

DR. WILLIAM O. RICHARDS (NASHVILLE, TENNESSEE): Thank you for your comments. Yes, previously when we espoused the idea that you should only do a myotomy alone without a partial fundoplication we felt that an important mechanism of reflux barrier was the fact that we did not take down the phrenoesophageal membrane laterally or posteriorly, and did not create a hiatal hernia.

DR. RICHARD J. FINLEY (VANCOUVER, BRITISH COLUMBIA, CANADA): I have 3 questions. Was your dysphagia score patient derived and validated? Do you have any objective evidence on esophageal transit, either liquid or solid, to see whether transit was the same in both groups? And did you anchor the non-Dor-Fundoplication myotomy in the abdomen or did you leave it alone? And if you left it alone, have any of those patients developed a hiatal hernia?

DR. WILLIAM O. RICHARDS (NASHVILLE, TENNESSEE): Our dysphagia score is not validated. There is no dysphagia score out there, to my knowledge—that is a validated quality-of-life questionnaire. We have not done esophageal transit studies, although we are planning to embark on those in the near future. In terms of anchoring the standard Heller myotomy, we do not anchor the standard Heller myotomy unless they have a preexisting hiatal hernia at the time of surgery, in which case we would repair the hiatal hernia and anchor it within the abdomen and perform a Dor-Fundoplication. Now we always do the Dor-Fundoplication in all patients undergoing Heller myotomy,

DR. LAWRENCE W. WAY (SAN FRANCISCO, CALIFORNIA): I think this is an outstanding study. But I just wonder whether the most pressing question has been addressed in the following sense. For many years it has been unclear as to what the best operation should be because a trial such as yours had not been done. The debate was between a group—I guess the most prominent member was Henry Ellis—who said that one could do a myotomy that was extended only a short distance, like 5 millimeters, into the stomach and the dysphagia would be relieved and reflux would be avoided by this precisely made

short myotomy. Others—I guess the most prominent was Professor Peracchia—argued that a longer myotomy was necessary to overcome the dysphagia and that should be accompanied by Dor-Fundoplication. Both groups pressed their arguments.

We found that it was difficult or impossible to re-create the claims that were made for the short myotomy, because our patients had asymptomatic reflux. And that is why we went to the other camp. Because we started believing that we could do a short myotomy and get good results. We got good results, but there was still unexpected reflux in these patients. So the question still stands.

I don't think anybody supposed that these long myotomies would be free of reflux. That has not previously been

a claim. And so I wonder whether your control group without a fundoplication is really always as appropriate as it might seem for this traditional debate that has gone on for as long as 40 years.

DR. WILLIAM O. RICHARDS (NASHVILLE, TENNESSEE): I think the real impetus for doing this study was a meta-analysis done by Lyass and Ed Phillips at Cedars-Sinai. Basically they showed that the incidence of pathologic GERD after Heller myotomy alone was only 10%. That supports our contention that this was an appropriate trial to test the efficacy of Dor-Fundoplication to reduce pathologic reflux after Heller myotomy.