

# Congenital Retinal MacrovesSEL. A Case Report of a Rare Incidental Finding

Samar A. Bukhatwa<sup>1</sup>  Mervat A. Omear<sup>2</sup>

<sup>1</sup>Ophthalmology Department, Faculty of Medicine, University of Benghazi, Benghazi, Libya

<sup>2</sup>Department of Ophthalmology, Sidi Hussein Health Center, Libya

Address for correspondence Samar A. Bukhatwa, Ophthalmology Department, Faculty of Medicine, University of Benghazi, Benghazi, Libya (e-mail: samar.bukhatwa@uob.edu.ly).

Libyan Int Medical Univ J 2023;8:47–50.

## Abstract

Congenital retinal macrovesSEL (CRM) is a rare vascular abnormality of the macular region that is usually discovered incidentally.

We present the case of a 57-year-old Libyan female patient with a CRM.

The patient's left eye showed an abnormally large retinal vein crossing the foveal avascular region, Optical coherence tomographic angiography (OCTA) showed a large retinal vessel in the left eye branching superiorly at the edge of the fovea a vascular zone. The patient has no visual defect or macular thickening.

CRM is an incidental finding that, with rare exceptions, does not cause any alteration to the patient's vision. They can be imaged by OCTA and need to be differentiated from other retinal pathologies.

## Keywords

- ▶ congenital retinal macrovesSEL
- ▶ fovea
- ▶ optical coherence tomographic angiography

## ملخص المقال باللغة العربية

الأوعية الكبيرة للشبكية الخلقي، تقرير حالة عن اكتشاف عرضي نادر

### المؤلفون:

سمر بوخطوة، قسم طب وجراحة العيون، كلية الطب، جامعة بنغازي، ميرفت عمير مركز سيدي حسين الصحي، بنغازي، ليبيا.

المؤلف المسؤول: سمر بوخطوة، البريد الإلكتروني: [samar.bukhatwa@uob.edu.ly](mailto:samar.bukhatwa@uob.edu.ly)

الأوعية الكبيرة للشبكية الخلقي هو خلل نادر في الأوعية الدموية في المنطقة البقعية للشبكية، وهي عادة ما يتم اكتشافها بالمصادفة. هذا وصف لمرضية ليبية تبلغ من العمر 57 عاماً أظهرت وجود وريد شبكي كبير غير طبيعي يعبر منطقة الأوعية الدموية النقية بعينها اليسرى. أظهر تصوير الأوعية المقطعي بالتماسك البصري أوعية شبكية كبيرة في العين اليسرى متفرعة بشكل علوي عند المنطقة الوعائية لحافة النقرة بالشبكية. هذا الخلل الخلقي لم يسبب للمرضية أي عيب بصري كما أن السماكة البقعية للشبكية كانت طبيعية.

الأوعية الكبيرة للشبكية الخلقي هو اكتشاف عرضي، مع استثناءات نادرة، لا يسبب أي تغيير في الرؤية للمريض، يمكن تصويره بواسطة التماسك البصري للتصوير المقطعي للأوعية، ويحتاج إلى التمييز بينه وبين أمراض الشبكية الأخرى.

الكلمات المفتاحية: الأوعية الكبيرة للشبكية الخلقي، النقرة، تصوير الأوعية المقطعي بالتماسك البصري.

article published online  
July 25, 2023

DOI <https://doi.org/10.1055/s-0043-1771178>.  
ISSN 2519-139X.

© 2023. The Author(s).

This is an open access article published by Thieme under the terms of the Creative Commons Attribution License, permitting unrestricted use, distribution, and reproduction so long as the original work is properly cited. (<https://creativecommons.org/licenses/by/4.0/>)  
Thieme Medical and Scientific Publishers Pvt. Ltd., A-12, 2nd Floor, Sector 2, Noida-201301 UP, India

## Introduction

Brown et al used the term congenital retinal macrovesSEL (CRM) to describe an abnormal retinal vessel, generally a vein, that extends through the central macula, supplying or draining regions above and below the horizontal raphe. This abnormality is frequently unilateral and seldom affects vision.<sup>1</sup> CRM was later categorized as a type (stage 1) of arteriovenous malformation of the retina by Archer et al.<sup>2</sup>

Optical coherence tomography angiography (OCTA) now allows for noninvasive imaging of retinal vasculature and segmentation of the superficial and deep vascular layers.<sup>3</sup>

This case report was conducted in adherence to the principles of the Helsinki Declaration. It was authorized by the ethical board of Benghazi Ophthalmology Teaching Hospital, and informed written permission was acquired after discussing the study with the patient.

In this study, we present the case of a patient with a CRM crossing the foveal avascular region, with no visual defect or macular thickening.

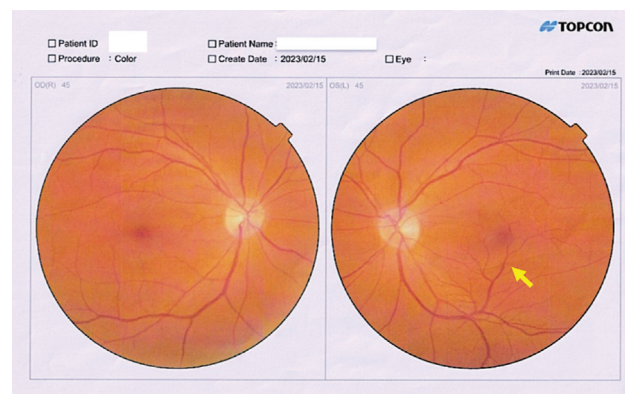## Case Presentation

A 57-year-old woman presented to the ophthalmology (OPD) asking for changing her reading glasses. On examination, both eyes' best corrected visual acuity was 0.9, intraocular pressure was within normal limits, and anterior segment examination was normal. Posterior segment examination with +90-D lens revealed no abnormality in the right eye,

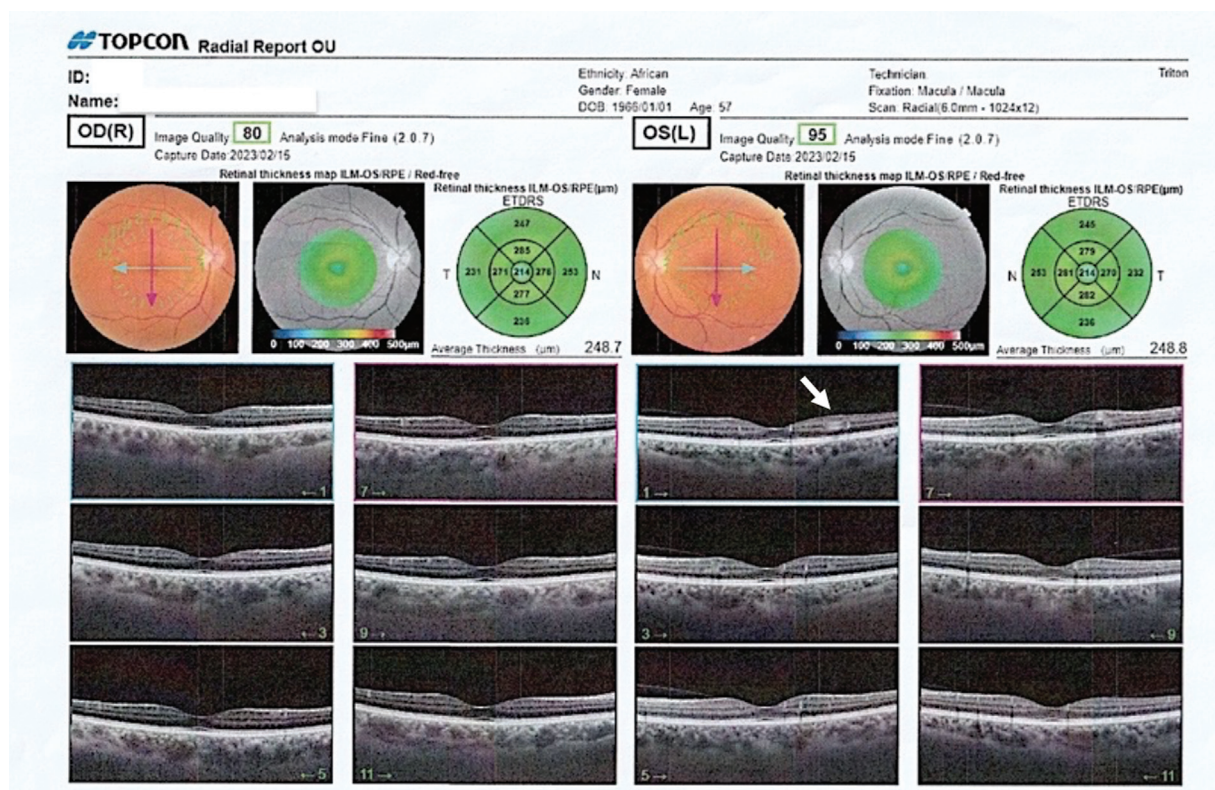
while in the left eye, it showed an abnormal, large retinal vein (macrovesSEL) branching superiorly from the inferotemporal vein, with numerous tributaries crossing the horizontal raphe across the macula, adjacent to the fovea. A color fundus photograph of both eyes is shown in **Fig. 1**.

Optical coherence tomography (OCT) was done; the left eye showed a small hyperreflective lesion corresponding to the location of the macrovesSEL (see **Fig. 2**).

Optical coherence tomographic angiography (OCTA; DRI OCT Triton plus, Topcon Medical Systems, Inc., Europe) was normal for the right eye. It detected no alterations, except for the presence of the macrovesSEL branching superiorly at the edge of the fovea, a vascular zone in the left eye (**Fig. 3**).

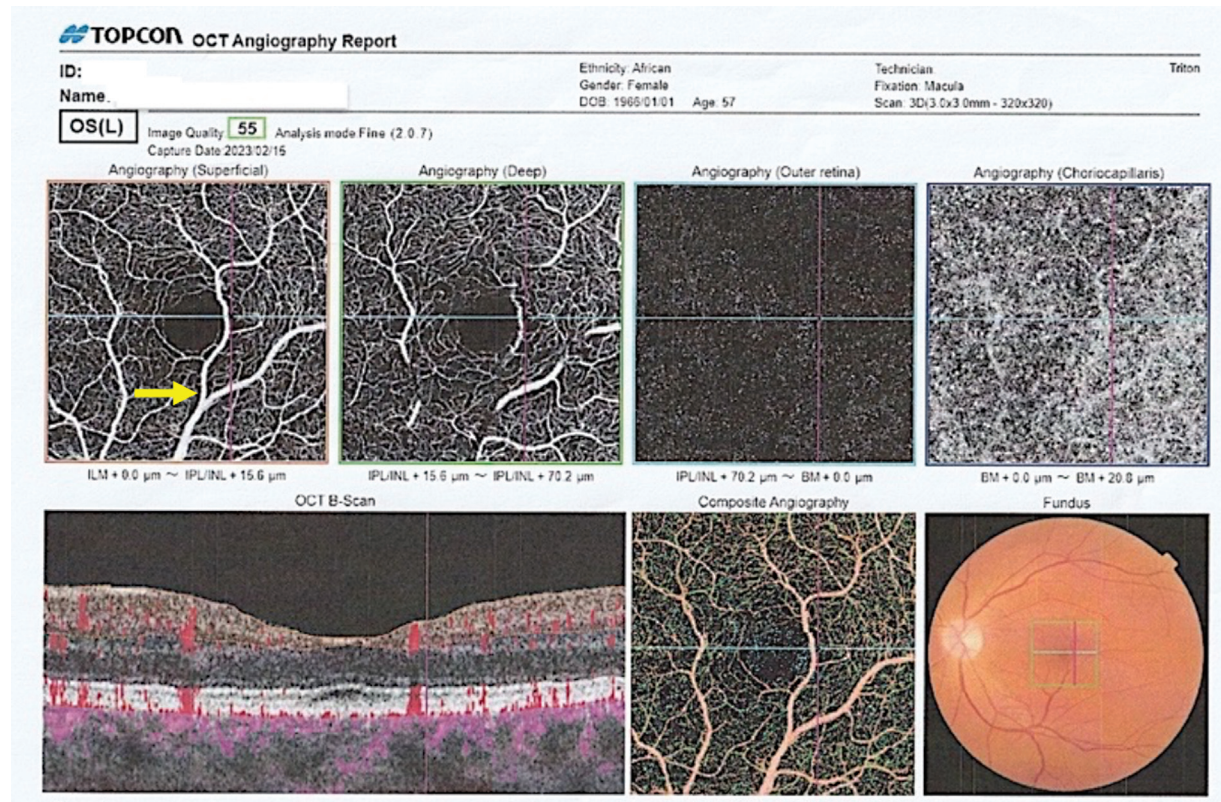


**Fig. 1** Color fundus photographs of the right eye (OD) and left eye (OS), showing a left eye macrovesSEL.



**Fig. 2** Optical coherence tomography (OCT), showing a normal right eye (OD) and a small hyperreflective lesion (arrow) corresponding to the location of the macrovesSEL in the left eye (OS).





**Fig. 3** A  $3 \times 3$  mm en face optical coherence tomographic angiography (OCTA) images of the left eye (OS). Images were segmented into superficial (upper limit:  $0 \mu\text{m}$  from the internal limiting membrane; lower limit:  $15 \mu\text{m}$  posterior to the inner plexiform layer [IPL]) and deep (upper limit:  $15 \mu\text{m}$  posterior to the IPL; lower limit:  $70 \mu\text{m}$  posterior to the IPL) showing large retinal vessels branching superiorly at the edge of the fovea, a vascular zone (arrow).

## Discussion

CRM is a rare vascular abnormality of the macular region that is usually discovered incidentally.<sup>4</sup>

The majority of cases of CRM are asymptomatic and stationary, although they have been described in association with other retinal alterations such as macular hemorrhages, preretinal hemorrhages, perifoveal microvascular alterations,<sup>5</sup> central serous chorioidopathy,<sup>6</sup> arterial macroaneurysms,<sup>7</sup> retinopathy of prematurity,<sup>8</sup> vascular occlusion, cystic macular edema (which resolves spontaneously after a few months),<sup>9,10</sup> vascular malformations of the central nervous system,<sup>9,11</sup> and reduced retinal sensitivity at the macular area.<sup>12</sup>

Although the CRMs are apparent and stable vessels that cross the foveal avascular zone, a fundus examination may not always reveal their existence. Therefore, in the case of unexplained vision loss, the ophthalmologist should investigate such a rare possibility.<sup>5</sup>

OCTA has been proven to be a viable method for imaging the superficial and deep vascular layers of the retina. It is quick, noninvasive, and does not need fluorescein dye.<sup>13</sup>

## Conclusion

In conclusion, CRM or aberrant vessels are incidental findings that, with rare exceptions, do not cause any alteration to

the patient's vision. They can be imaged by OCTA and need to be differentiated from other retinal pathologies.

### Funding

None.

### Conflict of Interest

None declared.

## References

- Brown GC, Donoso LA, Magargal LE, Goldberg RE, Sarin LK. Congenital retinal macrovessels. *Arch Ophthalmol* 1982;100(09):1430–1436
- Archer DB, Deutman A, Ernest JT, Krill AE. Arteriovenous communications of the retina. *Am J Ophthalmol* 1973;75(02):224–241
- Sampson DM, Dubis AM, Chen FK, Zawadzki RJ, Sampson DD. Towards standardizing retinal optical coherence tomography angiography: a review. *Light Sci Appl* 2022;11(01):63
- Petropoulos IK, Petkou D, Theoulakis PE, Kordelou A, Pournaras CJ, Katsimpris JM. Congenital retinal macrovessels: description of three cases and review of the literature. *Klin Monatsbl Augenheilkd* 2008;225(05):469–472
- de Crecchio G, Alfieri MC, Cennamo G, Forte R. Congenital macular macrovessels. *Graefes Arch Clin Exp Ophthalmol* 2006;244(09):1183–1187
- Ascaso FJ. Spontaneous resolution of central serous chorioretinopathy in a patient with congenital retinal macrovessel. *Circulation* 2011;124(25):e904–e905

- 7 Goel N, Kumar V, Seth A, Ghosh B. Intravitreal bevacizumab in congenital retinal macrovesSEL with retinal arteriolar macroaneurysm. *Saudi J Ophthalmol* 2015;29(04):292–294
- 8 Han JR, Jeon GS, Park JH, Seong HK, Nam WH, Kim HK. Congenital retinal macrovesSEL and foveal dysplasia of retinopathy of prematurity. *Jpn J Ophthalmol* 2009;53(03):277–279
- 9 Sanfilippo CJ, Sarraf D. Congenital macrovesSEL associated with cystoid macular edema and an ipsilateral intracranial venous malformation. *Retin Cases Brief Rep* 2015;9(04):357–359
- 10 Arai J, Kasuga Y, Koketsu M, Yoshimura N. Development and spontaneous resolution of serous retinal detachment in a patient with a congenital retinal macrovesSEL. *Retina* 2000;20(06):674–676
- 11 Pichi F, Freund KB, Ciardella A, et al. Congenital retinal macrovesSEL and the association of retinal venous malformations with venous malformations of the brain. *JAMA Ophthalmol* 2018;136(04):372–379
- 12 Shah VA, Chalam KV. Congenital retinal macrovesSEL causes reduced retinal sensitivity at the macula. *Eur J Ophthalmol* 2004;14(04):341–344
- 13 Jia Y, Bailey ST, Hwang TS, et al. Quantitative optical coherence tomography angiography of vascular abnormalities in the living human eye. *Proc Natl Acad Sci U S A* 2015;112(18):E2395–E2402